

ICPESK 2017
International Congress of Physical Education, Sport and
Kinetotherapy

LUMBAR DISCOPATHY IN ATHLETES

Mihai Popescu (a), Octavian Horatiu Rusu (b)*, Cristian Gabriel Popescu (c)

*Corresponding author

(a) University of Pitești, County Emergency Hospital, 36 Aleea Spitalului Street, Pitești, Romania,
mihaiopescu2000@yahoo.com

(b) National University of Physical Education and Sports, 140 Constantin Noica Street, Bucharest, Romania,
octavianhoratiurusu@rocketmail.com

(c) “Bagdasar-Arseni” Clinical Emergency Hospital, 12 Berceni Street, Bucharest, Romania,
cristianpopes@yahoo.com

Abstract

This paper presents our experience (at the Neurosurgery Department of Pitești County Emergency Hospital) over a period of 5 years, in terms of lumbar discopathy manifested as lumbar sciatica in athletes. Lumbar discopathy is a relatively frequent disease in athletes who practice contact sports, on the one hand, and on the other hand, in athletes who excessively stress their lumbar spine through repeated micro traumatism. The objective is the clinical and paraclinical diagnosis of back pain of the lumbar spine, directly related to its overstress, depending on the practiced sport. It is a simple statistical study carried out on a total of 17 patients who have come to our healthcare unit, all practicing high-performance sports. A causal link between the practiced sport and the disease onset was established anamnestically and clinically, namely the clinical progression of lumbar sciatica. Paraclinical examinations, i.e. computed tomography and nuclear magnetic resonance, confirmed the existence of disc pain in these patients, showing disc injuries of different intensity. Lumbar discopathy has two major aetiological causes: violent trauma of the lumbar spine, with post traumatic disc herniation: 2 cases; repeated micro traumatism, with progressive lesions of the posterior longitudinal ligament, the fibrous ring and nucleus pulposus, causing disc herniation.

© 2018 Published by Future Academy www.FutureAcademy.org.UK

Keywords: Lumbar discopathy, lumbar disc herniation, lumbar sciatica, radicular arteries, treatment.



1. Introduction

This paper presents our experience (at the Neurosurgery Department of Pitești County Emergency Hospital) over a period of 5 years, in terms of lumbar discopathy manifested as lumbar sciatica in athletes. Lumbar discopathy is a relatively frequent disease in athletes who practice contact sports, on the one hand, and on the other hand, in athletes who excessively stress their lumbar spine through repeated micro traumatism.

2. Problem Statement

Athletes need to know that they are predisposed to lumbar discopathy as a future effect of repeated efforts and micro traumatism, and that the occurrence of such pains involves a physical training regimen adapted to suffering. Conservative treatment must be individualised by the physician and physiotherapist in such a way as to ensure a quasi-positive improvement in symptoms and to determine the exact moment of resumption of performance when there is no risk of worsening or recurrence of the disease.

3. Research Questions

- May lumbar spine trauma, either major or recurrent micro traumatism, be considered as the aetiological factors of this disease?
- Do you consider that, in the case of performance athletes, repeated poly-traumatism may be the possible cause of lumbar vertebral discopathy?
- Are the paraclinical investigations (MRI, CAT scan) and the objective neurological examination necessary for the correct diagnosis of lumbar vertebral discopathy?

4. Purpose of the Study

Overloading the spine is a determining factor in certain sports branches, which can cause lumbar vertebral discopathy or even herniated disc.

Conservative treatment of the lumbar vertebral discopathy is done in a mixed team: physician and physiotherapy teacher.

The role of coach and physical therapist is essential in driving and grading recovery so that the athlete can be reintegrated into normal parameters.

The degree and quantity of the specific effort is made at the direction of the coach, under the guidance of the physical therapist.

The purpose of the research is to demonstrate that the physician, the trainer and the physiotherapy teacher have an essential role in managing and grading the recovery until the athlete is reintegrated into normal parameters.

5. Research Methods

The objective is the clinical and paraclinical diagnosis of back pain of the lumbar spine, directly related to its overstress, depending on the practiced sport. It is a simple statistical study carried out on a total of 17 patients who have come to our healthcare unit, all practicing high-performance sports.

Traumatic hernias are more common in contact sports: wrestling, judo, rugby, etc., traumas that can cause even more serious injuries: spinal fractures, traumatic disco-radicular injuries, lumbar medullary compression syndromes with tetraplegia or paraplegia, definitive traumatic lesions, according to Schmidek and Sweet (1995).

Rusu (1983) argues that lumbar discopathy through repeated micro traumatisms occurs in sports that involve efforts of medium intensity applied on the lumbar spine and overstress on the paravertebral muscles, such as: handball, football, tennis, table tennis, basketball, volleyball. Of the cases diagnosed and investigated by us, 16 could be treated conservatively, as the diagnosis was made early and the osteodiscal lesions did not produce a major compression of the nervous element, only one having surgical indication.

Diagnosis is based on clinical data, i.e. sciatica neuralgia, neurological examination and paraclinical investigations (Electromagnetic resonance, CAT scan).

The distribution of pain by sport is the following: football - 4 sick people, basketball - 3, rugby - 3, tennis - 3, volleyball - 2, wrestling - 2.

6. Findings

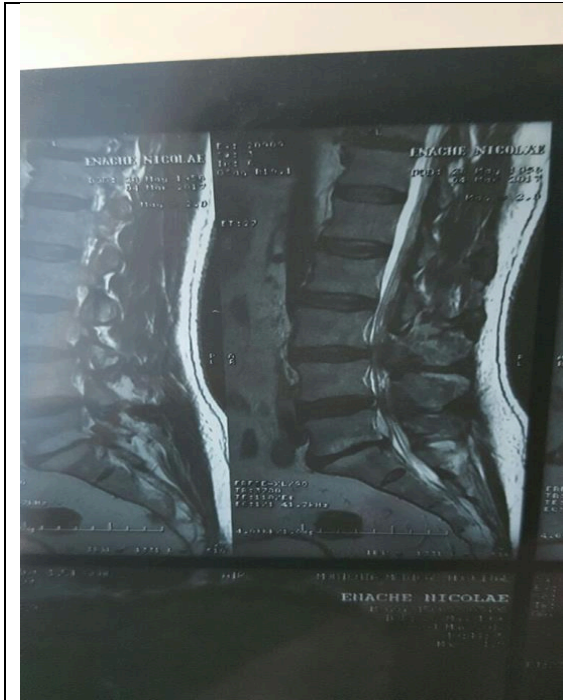
Conservative treatment is represented by bed rest avoiding flexion-rotation movements of the lumbar spine, decontracting massage of the lumbar muscles, re-education of the vertebral statics – the Williams method being preferred by us, anti-inflammatory drug treatment, muscle decontraction and, in some cases, corticosteroid administration, as Seeger (1982) told in this book.

Whitesides et al. (2005) speak about the surgical treatment of lumbar disc herniation, which involves, as a surgical technique, fenestrectomy with foraminotomy in the herniated disc, followed by ablation of the disc by extradural discectomy.

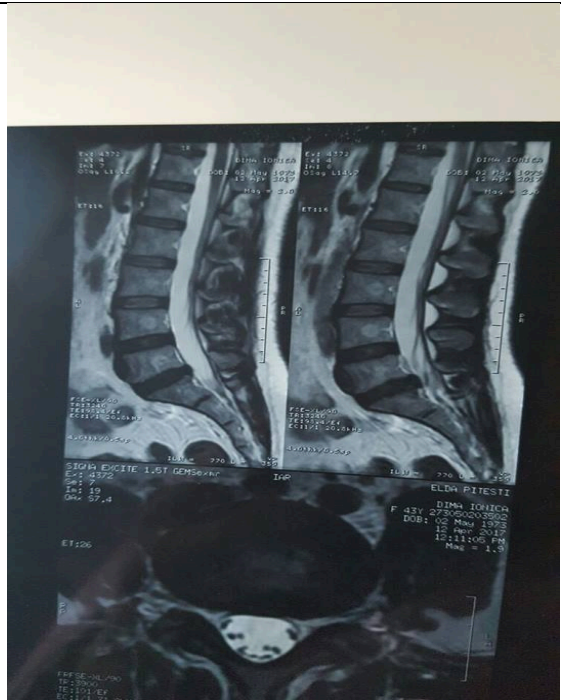Sindou (2001) reports that medical rehabilitation is done progressively, and resumption of training and sports activity is done gradually, under medical supervision, from a few days to a few weeks, the major criterion for prolonging the treatment and limiting performance training being the persistence or recurrence of lumbar sciatica symptoms.

Here are some images of MRI patients:

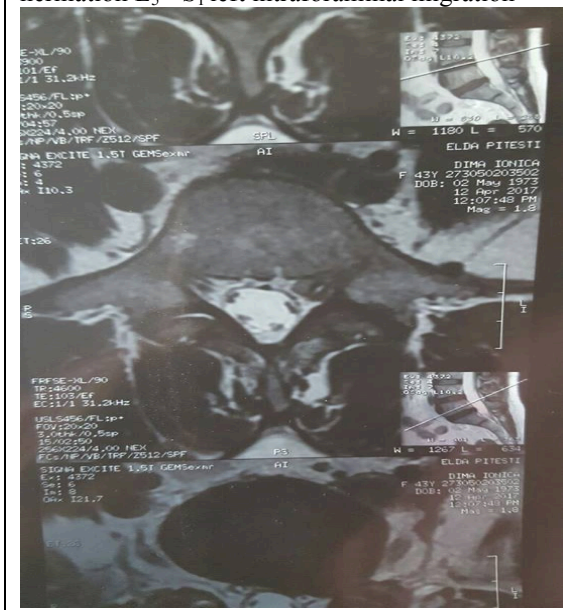PICTURE 1 (E. N.) Lumbar spine MRI, Sequence T ₂ sagittal, aspect of lumbar poly-discopathy L ₃ - L ₄ , L ₄ - L ₅ , L ₅ - S ₁ Osteocondensation of plateaus L ₅ - S ₁	PICTURE 2 Lumbar spine MRI, disc herniation, L ₅ - S ₁ sub-ligamentous tear
--	--



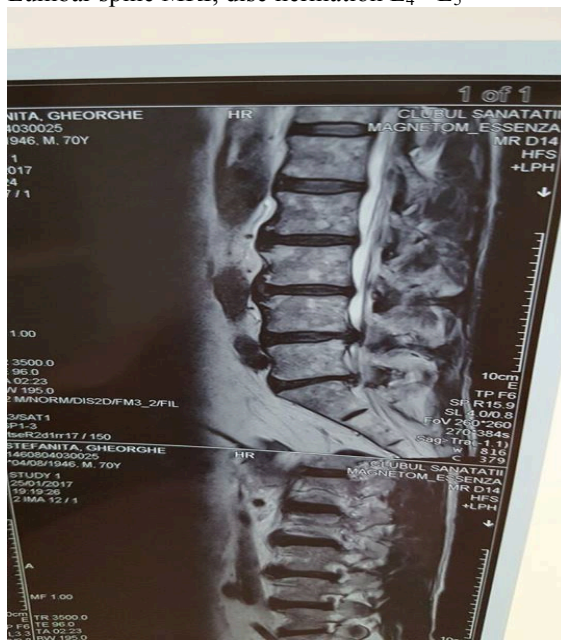
PICTURE 3 - (D. I.)
 Lumbar spine MRI, Sequence T₂ axial, disc herniation L₅ - S₁ left intraforaminal migration

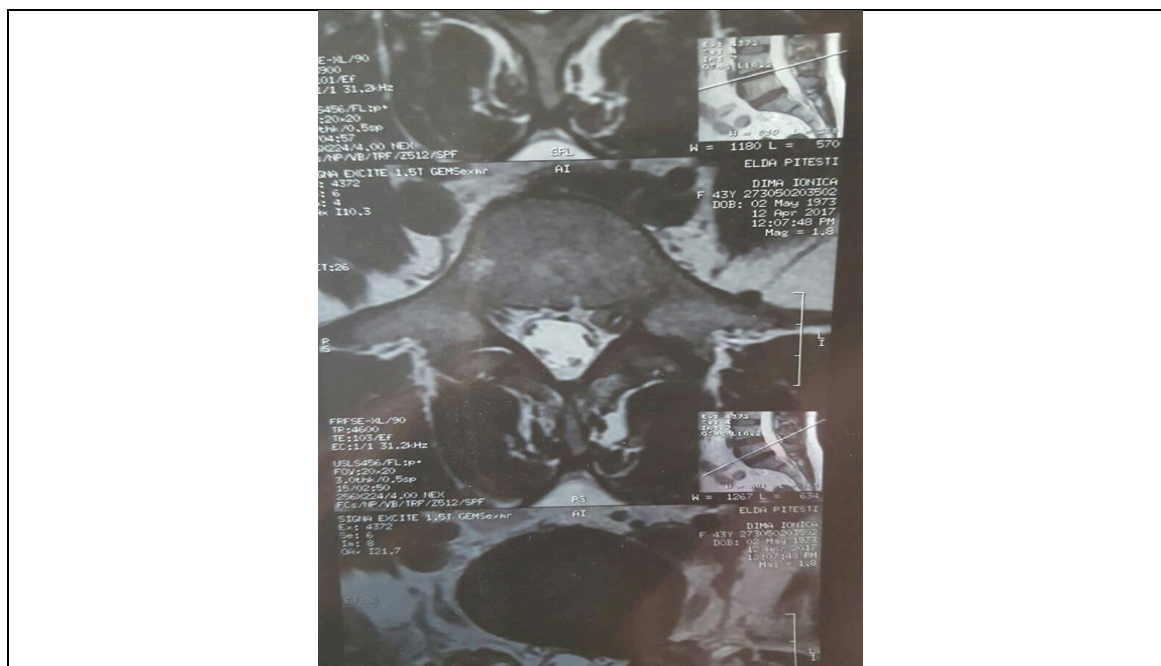


PICTURE 4 - (N.G.)
 Lumbar spine MRI, disc herniation L₄ - L₅



PICTURE 5
 Lumbar spine MRI, Sequence T₂ axial, disc herniation L₅ - S₁ paramedian left





7. Conclusion

As a final conclusion, athletes need to know that they are predisposed to lumbar discopathy as a future effect of repeated efforts and micro traumatism, and that the occurrence of such pains involves a physical training regimen adapted to suffering. Conservative treatment must be individualised by the physician and physiotherapist in such a way as to ensure a quasi-positive improvement in symptoms and to determine the exact moment of resumption of performance when there is no risk of worsening or recurrence of the disease.

We believe that, in these cases of lumbar vertebral poly-discopathy, the stages of the recovery program must be rigorously drawn up in a close collaboration between physician, physical therapist and coach.

In this context, practice demonstrates that athletes such as Roger Federer, Rafael Nadal, Gianluigi Buffon, who suffered from these poly-traumatism, have managed, through adequate recovery, to continue their competitive activity at the highest level.

References

- Rusu, M. (1983). Hernia de disc. Studiu anatomo-clinic comparativ pe două loturi de bolnavi la un interval de 25 de ani. *Neurologia, Psihiatria, Neurochirurgia*, 4, 293-305.
- Schmidek, H. H., & Sweet, W. H. (1995). *Operative neurosurgical techniques*. Saunders Co.
- Seeger, W. (1982). *Microsurgery of the spinal cord and surrounding structures*. Springer.
- Sindou, M. (2001). *Curs de neurochirurgie*. Iași: Ed. Gh. Asachi.
- Whitesides, T. E. Jr., Horton, W. C., Hutton, W. C., & Hodges, L. (2005). Spondylytic spondylolisthesis: A study of pelvic and lumbosacral parameters of possible etiologic effect in two genetically and geographically distinct groups with high occurrence. *Spine*, 30(6 Suppl), S12-21.